Evaluating the Feasibility of a Deep Learning-Based Atypical Cell Gallery for Clinical Diagnosis in Urine Cytology

Hsing-Ju Wu, Ph.D.

Show Chwan Memorial Hospital, Changhua, Taiwan

Conflict of Interest

- I have no conflicts of interest to disclose.

Educational Objectives

- Clinical evaluation of the effectiveness utilizing artificial intelligence (AI)-assisted digital urine cytology in diagnosing bladder cancer.
- Assessing the impact of AI integration on urine cytology reporting performance and time, relative to conventional microscopy and digital image review.
- The AI tool offers distinct advantages tailored to meet the specific clinical needs of cytopathologists and cytotechnologists.

Introduction

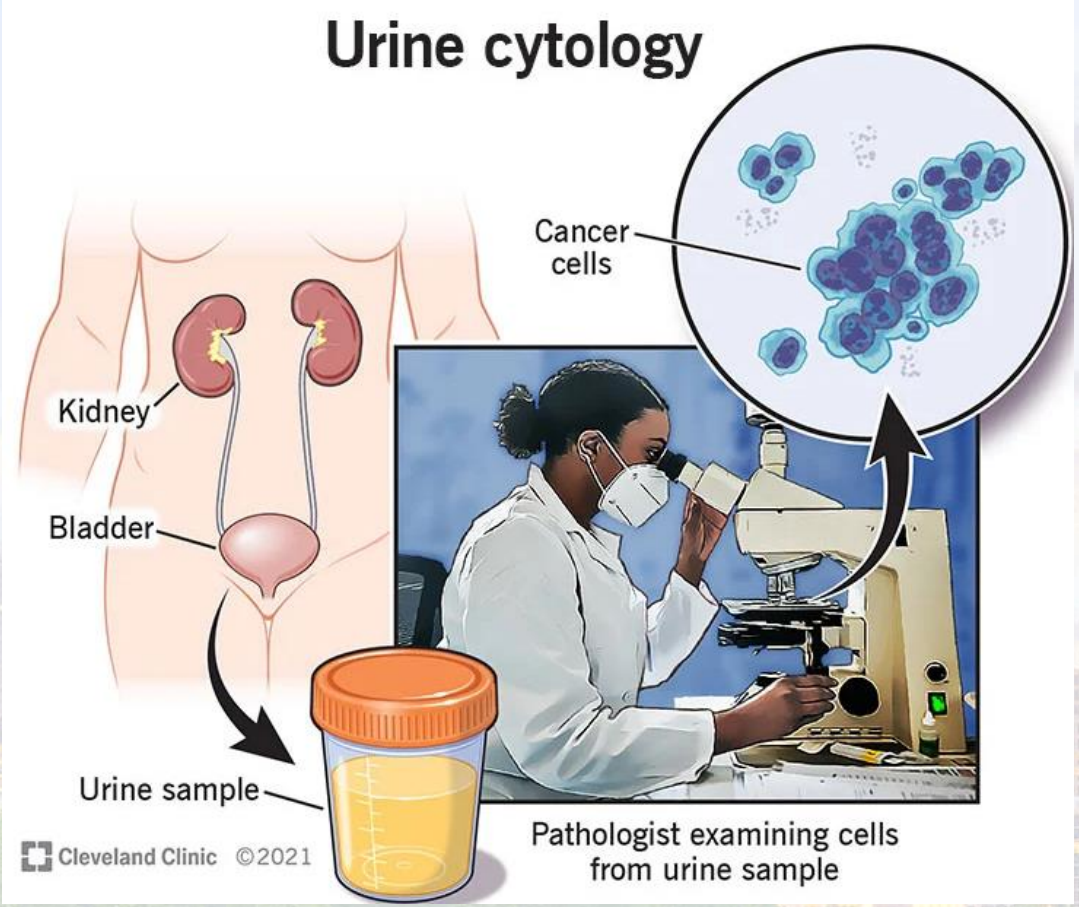

- An essential, non-invasive, and cost-effective method for identifying urothelial carcinoma, the major type of bladder cancer.
- Invaluable for diagnosing upper urinary tract urothelial carcinoma due to the limitations of cystoscopy.

Introduction

- Challenges of urine cytology: lower sensitivity, extended turnaround times, and inconsistent interpretations.
- Developed and tested a deep-learning AI algorithm for urothelial carcinoma diagnosis aligned with The Paris System (TPS) for Reporting Urine Cytology criteria.
- Investigated the feasibility of integrating digital urine cytology with AI into the current clinical workflow:

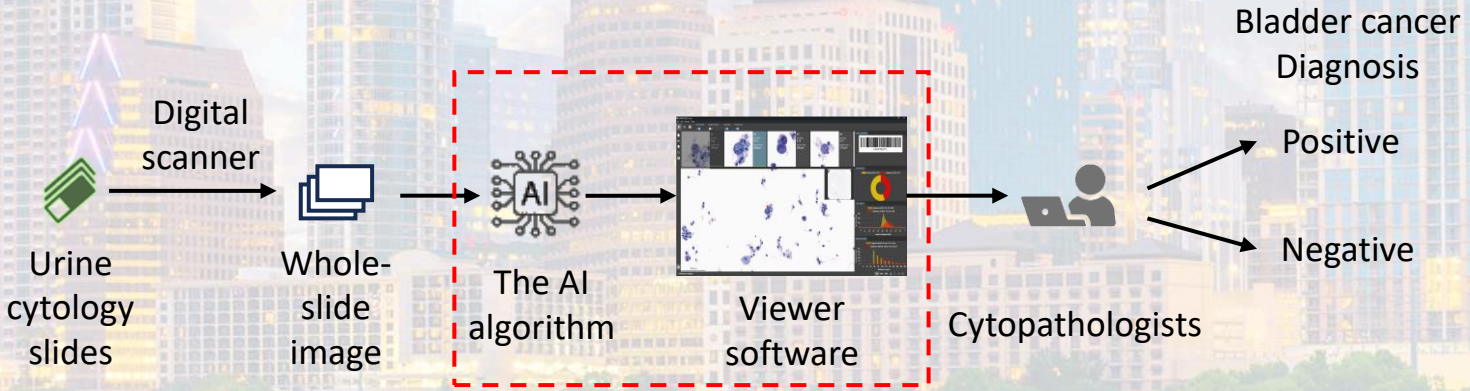

Central Aims

- Evaluate urine cytology reporting methods: conventional microscopy, digital image review, and AI-assisted digital image review.
- Analyze diagnostic results from three clinical readers, including one cytopathologist and two cytotechnologists, using different reporting methods.
- Assess integration of the AI-assisted method in the current urine cytology reporting workflow.
- ***Hypothesis: the AI-assisted method reduces diagnostic time and offers performance that is better or comparable to both microscopy and digital image review.***

Materials and Methods

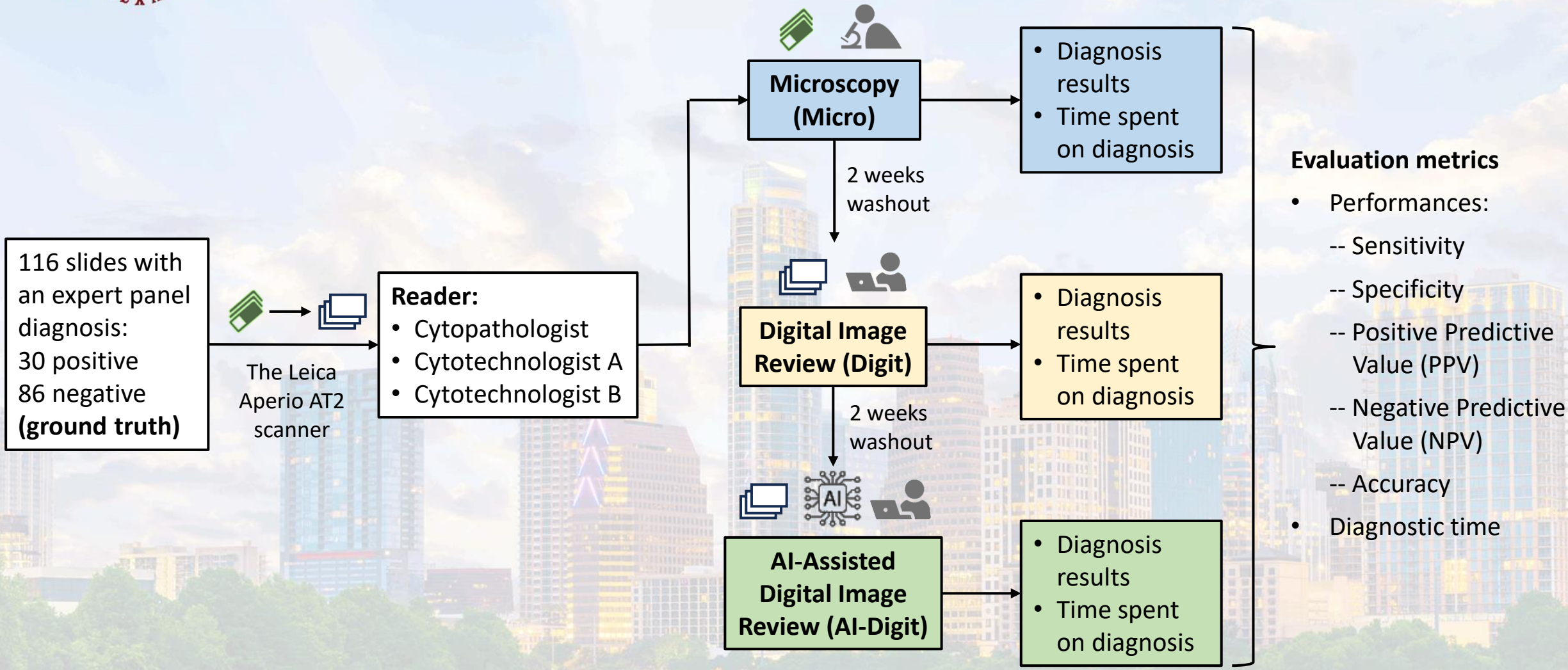

Materials and Methods

Digital Image Review (without AI-assisted)

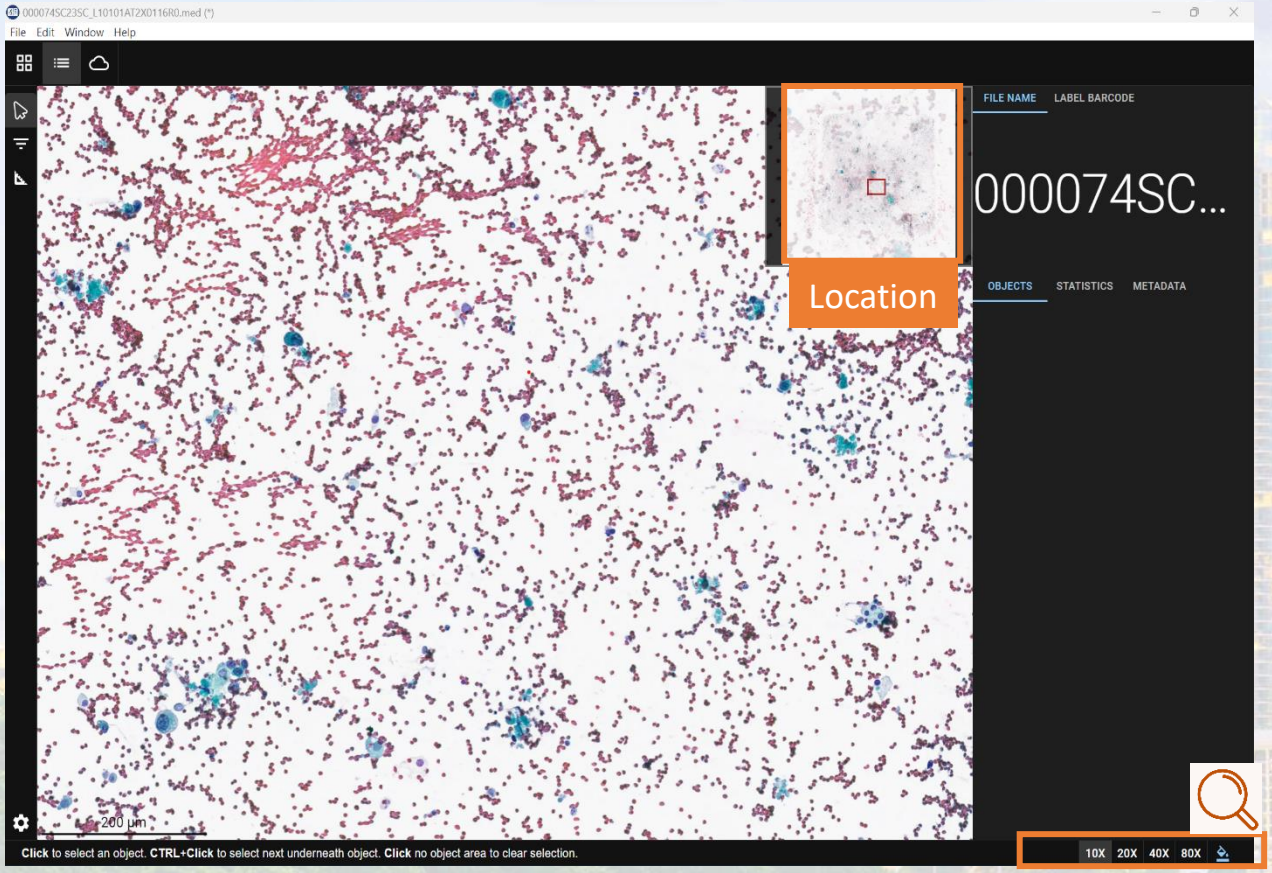

AI-Assisted Digital Image Review

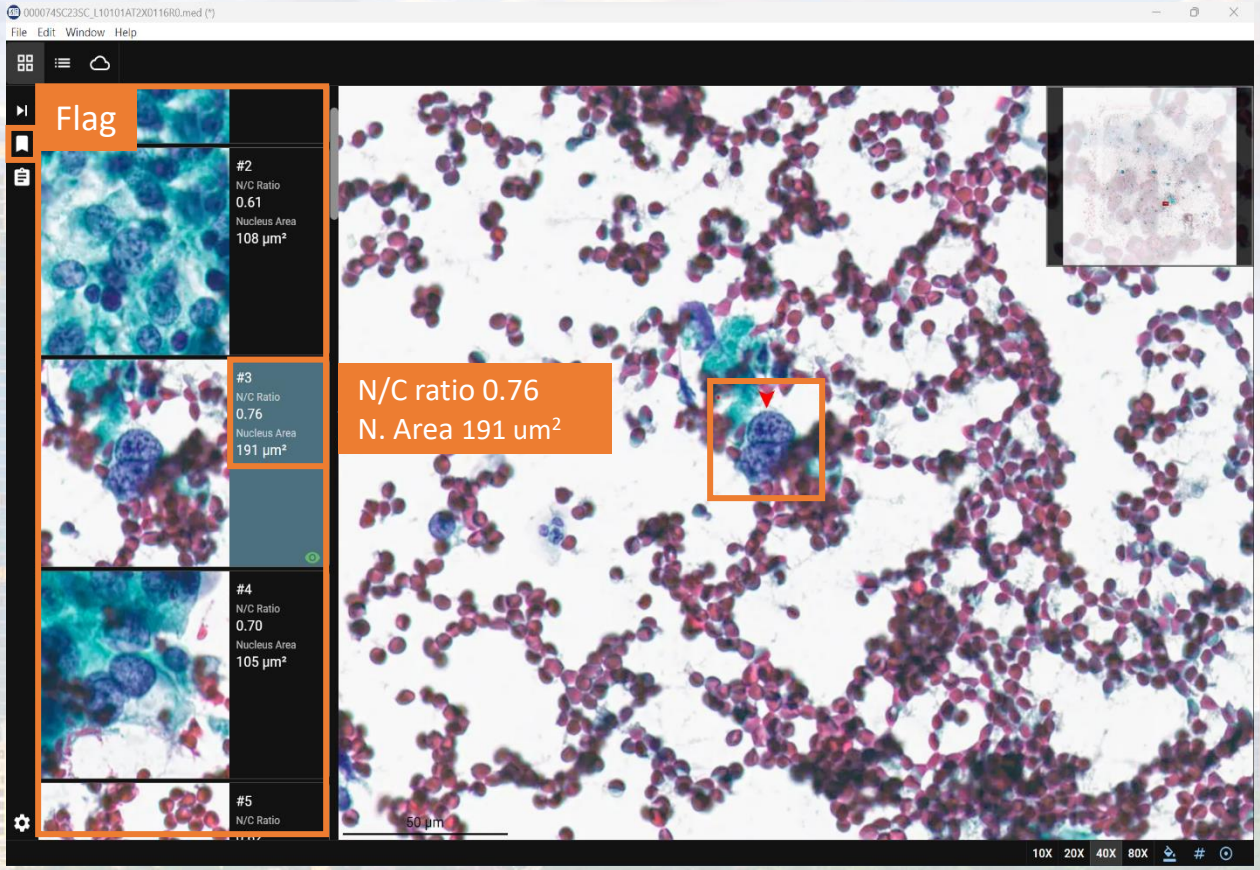

Results

Method	Microscopy (Micro)			Digital Image Review (Digit)			AI-Assisted Digital Image Review (Ai-Digit)		
Reader	Cytopathologist	Cytotech A	Cytotech B	Cytopathologist	Cytotech A	Cytotech B	Cytopathologist	Cytotech A	Cytotech B
Sensitivity	76.7%	93.3%	76.7%	76.7%	83.3%	73.3%	90.0%	100.0%	80.0%
Specificity	96.5%	70.9%	94.2%	93.0%	80.2%	84.9%	93.0%	60.5%	86.0%
PPV	88.5%	52.8%	82.1%	79.3%	59.5%	62.9%	81.8%	46.9%	66.7%
NPV	92.2%	96.8%	92.0%	92.0%	93.2%	90.1%	96.4%	100.0%	92.5%
Accuracy	91.4%	76.7%	89.7%	88.8%	81.0%	81.9%	92.2%	70.7%	84.5%

PPV: positive predictive value; NPV: negative predictive value

Results

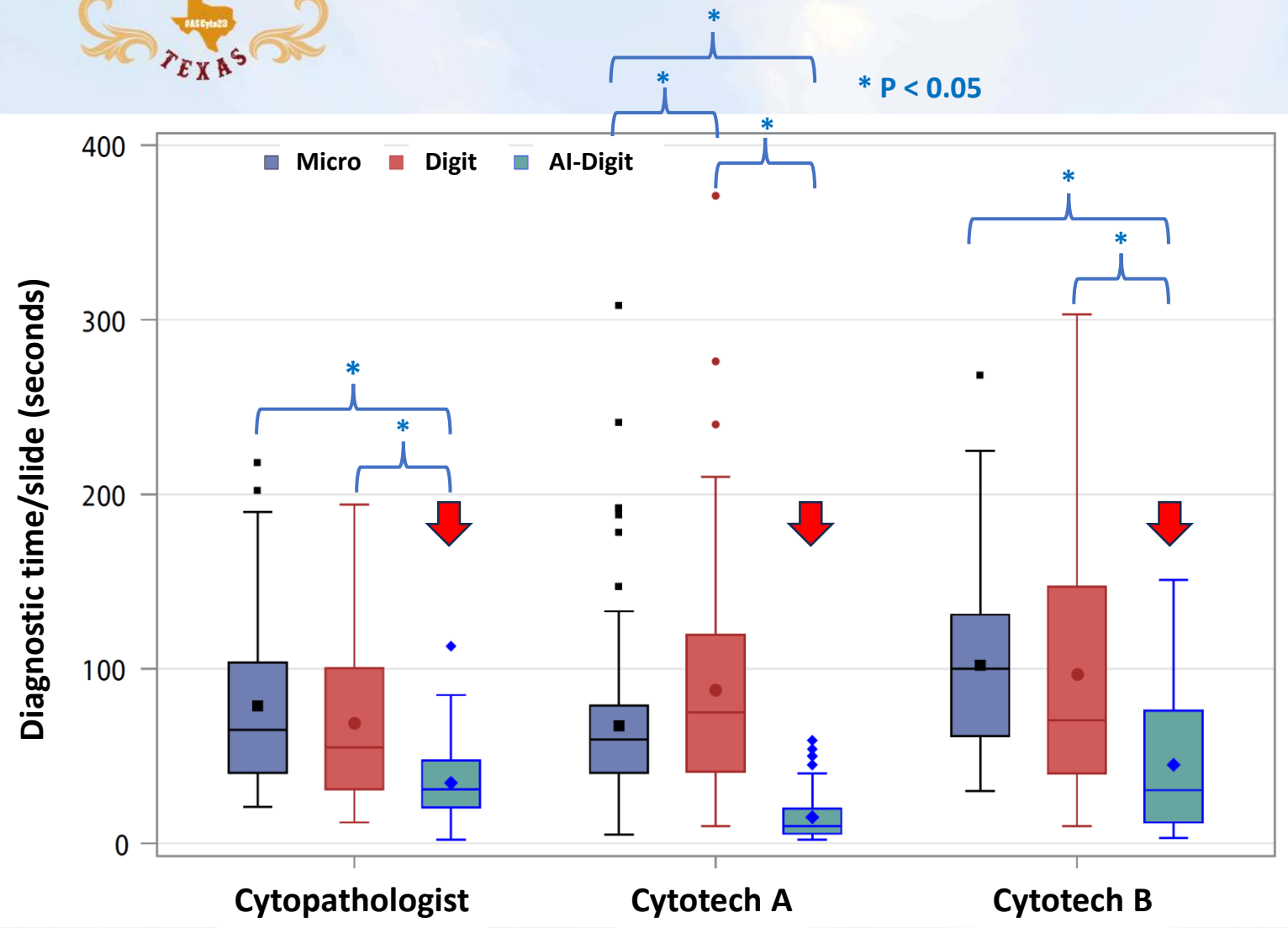

	Mean diagnostic time/slide (seconds)		
Reader/Method	Micro	Digit	AI-Digit
Cytopathologist	78.8	68.9	34.6
Cytotech A	67.3	88.1	15.0
Cytotech B	102.1	97.2	45.0

Discussion

- Potential benefits of integrating the AI-assisted method into clinical urine cytology reporting:
  1. The AI method outperformed microscopy and digital image review in sensitivity, NPV, accompanied by a marked reduction in interpretation duration.
  2. Clinical value of the AI method stands out when contrasted with digital image review results.
  3. Differences in reader performance indicate that the AI method could assist cytotechnologists in identifying more suspicious cases for further review by cytopathologists.

Evaluating Image Quality and Reproducibility of Digital Scanners for Whole-Slide Imaging in Urine Cytology Slides for Artificial Intelligence Applications

Wei-Lei Yang[1], Jen-Fan Hang[2,3], Yen-Chuan Ou[4], Tang-Yi Tsao[5], Tien-Jen Liu[1], Cheng-Hung Yeh[1], Shih-Wen Hsu[1] and Min-Che Tung[4]*

[1]AIxMed, Inc., Santa Clara, CA, USA; [2]Department of Pathology and Laboratory Medicine, Taipei Veterans General Hospital, Taipei, Taiwan; [3] School of Medicine and Institution of Clinical Medicine, National Yang Ming Chiao Tung University, Taipei, Taiwan; [4]Division of Urology, Department of Surgery, Tung's Taichung MetroHarbor Hospital, Taichung, Taiwan; [5]Department of Pathology, Tung's Taichung MetroHarbor Hospital, Taichung, Taiwan; *Correspondence to MC Tung ✉ tungminche@gmail.com

2023 ASC Annual Meeting
Poster#: PST118

Introduction

- While several FDA-approved commercial scanners exist for digital pathology, none are specifically tailored for urine cytology slides.
- Generating high-quality and consistent whole-slide images (WSIs) from cytology slides is essential for advancing digital cytopathology, however this area remains largely unexplored.
- We evaluated three digital scanners from two manufacturers regarding the image quality and reproducibility when scanning urine cytology slides.

Materials and Methods

- We examined 20 urine cytology slides, with five slides representing each of preparations: Cytospin, ThinPrep-non-GYN, ThinPrep-UroCyte, and SurePath.
- Three digital scanners were utilized: Roche DP200 and DP600, and Hamamatsu Nanozoomer S360, with the latter two being high-throughput versions.
- Each scanner was evaluated using three modes: default (auto focus), manual (manual focus), and advanced manual (manual placement of focus points). Triplicate images of each slide were obtained by using advanced manual mode.
- A deep-learning-based artificial intelligence (AI) analyzed all WSIs to identify atypical urothelial cells.
- Performance metrics were determined by the ratio of good-quality WSIs, as evaluated by two cytotechnologists, relative to the total slides scanned for each device. Reproducibility was assessed by analyzing variations in atypical cell numbers across triplicate slide images.

Results

Table 1. Good-quality whole-slide image rates for three digital scanners with three focus modes

	Roche DP200*			Roche DP600*			Hamamatsu Nanozoomer S360^		
Scan mode / Preparation	Default	Manual	Advanced manual	Default	Manual	Advanced manual	Default	Manual	Advanced manual
Cytospin	3/5 (60%)	4/5 (80%)	5/5 (100%)	3/5 (60%)	4/5 (80%)	2/5 (40%)	1/5 (20%)	4/5 (80%)	4/5 (80%)
ThinPrep-non-GYN	1/5 (20%)	0/5 (0%)	2/5 (40%)	2/5 (40%)	2/5 (40%)	3/5 (60%)	0/5 (0%)	4/5 (80%)	4/5 (80%)
ThinPrep-Urocyte	1/5 (20%)	3/5 (60%)	3/5 (60%)	3/5 (60%)	4/5 (80%)	2/5 (40%)	1/5 (20%)	4/5 (80%)	5/5 (100%)
SurePath	1/5 (20%)	1/5 (20%)	1/5 (20%)	2/5 (40%)	3/5 (60%)	2/5 (40%)	1/5 (20%)	3/5 (60%)	5/5 (100%)
Total	6/20 (30%)	8/20 (40%)	11/20 (55%)	10/20 (50%)	13/20 (65%)	9/20 (45%)	3/20 (15%)	15/20 (75%)	18/20 (90%)

* Focus mode: auto/manual "single" focus point placement for each region of interest
^ Focus mode: auto/manual "multiple" focus points placement for each region of interest

- In default mode, the Roche DP200/DP600 scanners produced good-quality WSI rate of 30% and 50%, respectively. Using manual and advanced manual modes, these rates increased to 40% and 65% (Table 1).
- The Hamamatsu scanner achieved a good-quality rate of 15% in default mode , but this increased dramatically to 75% and 90% when using the manual and advanced

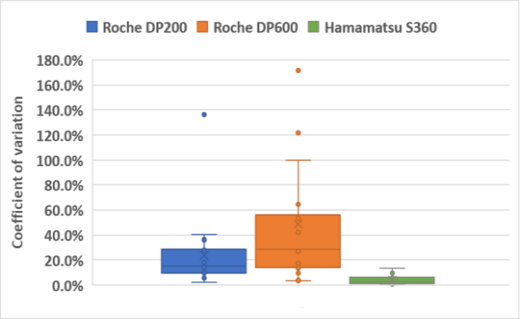

Figure 1. Coefficient of variation for atypical cell numbers from 20 cytology slides with different scanners

Figure 2. Distribution of coefficient of variation for atypical cell numbers from individual slides

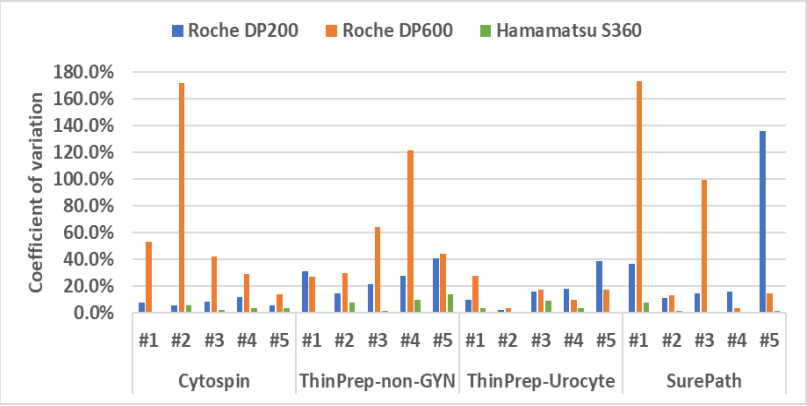

- The Hamamatsu scanner exhibited a lower coefficient of variation in AI-inferred atypical cell numbers from 20 cytology slides compared to Roche DP200/DP600 scanners (Figures 1).
- In an analysis of 20 slides sourced from four distinct preparations (with each preparation comprising five individual slides, each containing triplicate images), the Hamamatsu scanner showed lower coefficient of variation in the mean atypical cell numbers compared to both Roche scanners (Figure 2).

Conclusion

- Both Roche scanners performed better in achieving higher-quality WSI rates in default mode.
- The Hamamatsu scanner exhibited better performance in manual and advanced manual modes. The feature to manually select multiple focus points could enhance the performance of this scanner in digital urine cytology.
- The Hamamatsu scanner showed better reproducibility in detecting atypical urothelial cells across triplicate scans of the same slide.

Assessing an Artificial Intelligence-Driven Digital Cytology Tool for Efficient Diagnosis of Upper Tract Urothelial Carcinoma in Upper Urinary Tract Cytology

Wei-Lei Yang[1], Shih-Wen Hsu[1], Cheng-Hung Yeh[1], Tien-Jen Liu[1] and Jen-Fan Hang[2,3]*

[1]AIxMed, Inc., Santa Clara, CA, USA; [2]Department of Pathology and Laboratory Medicine, Taipei Veterans General Hospital, Taipei, Taiwan; [3]School of Medicine and Institution of Clinical Medicine, National Yang Ming Chiao Tung University, Taipei, Taiwan; *Correspondence to MC Tung ✉ tungminche@gmail.com

Taipei Veterans General Hospital

2023 ASC Annual Meeting Poster#: PST117

Introduction

- Cytological assessment of the upper urinary tract (UUT) is crucial for managing upper tract urothelial carcinoma (UTUC), but diagnosing suspicious lesions remains challenging.
- We examined an artificial intelligence (AI)-empowered digital cytology tool for improving the efficacy of UUT cytology interpretation.
- This tool detects atypical urothelial cells (AUCs) in whole-slide images (WSIs) and displays them in a visual gallery for rapid assessment, thus simplifying interpretation (Figure 1).

Materials and Methods

- In this retrospective study, we gathered 100 paired Cytospin and SurePath slides from 50 patients with UTUC and created digital WSIs by the Leica Aperio AT2 scanner.
- The AI algorithm analyzed each WSI, selecting and ranking the 24 most significant AUC images, then showcased them in a thumbnail gallery for cytologists' detailed examination (Figure 1).
- Three senior cytotechnologists, with varying experience using this AI tool (A: > 1 year; B: 6 months-1 year; C: < 1 month), evaluated the image galleries from each WSI and rendered a final interpretation based on The Paris System categories.
- We evaluated the efficacy and time-saving aspects of the AI-assisted tool for UUT cytology interpretation.

Figure 1. The image gallery of atypical urothelial cell images (left) and whole-slide image (right) in viewing software

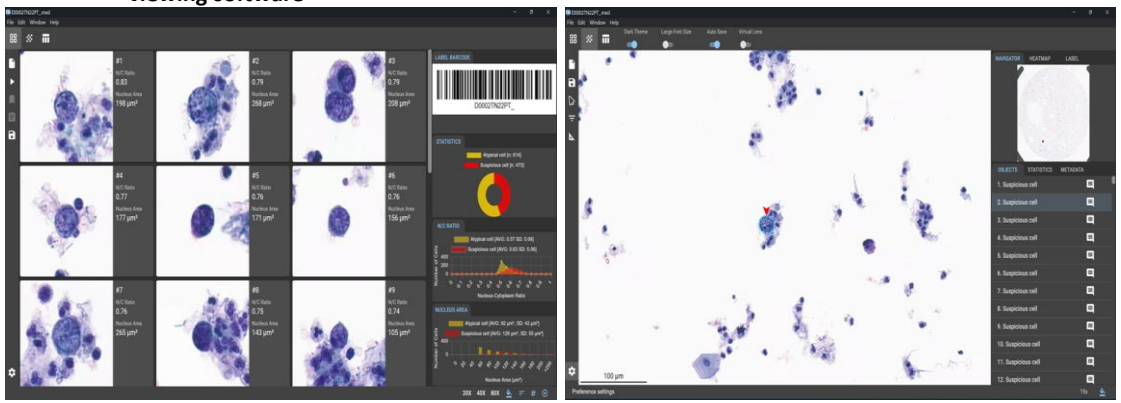

Results

Table 1. Performance of the AI-assisted tool in interpretating upper urinary tract cytology

Preparation	Cytospin (N = 50)				SurePath (N = 50)			
Reader	Ground Truth	Cytotech A	Cytotech B	Cytotech C	Ground Truth	Cytotech A	Cytotech B	Cytotech C
# Positive*	25	23	23	13	25	26	23	10
# Negative*	25	27	27	37	25	24	26	40
Sensitivity		88.0%	84.0%	52.0%		96.0%	87.5%	40.0%
Specificity		96.0%	92.0%	100.0%		92.0%	92.0%	100.0%
PPV		95.7%	91.3%	100.0%		92.3%	91.3%	100.0%
NPV		88.9%	85.2%	67.6%		95.8%	88.5%	62.5%
Accuracy		92.0%	88.0%	76.0%		94.0%	89.8%	70.0%

*Clinical interpretation: HGUC/SHGUC/AUC = Positive; NHGUC = Negative
PPV = positive predictive value; NPV = negative predictive value

Figure 2. Durations of examination for positive/negative slides by cytologists

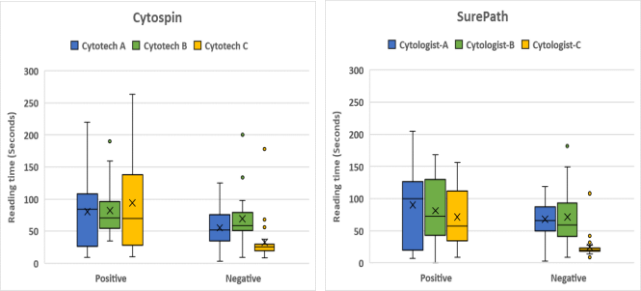

- There was no difference in the performance of cytotechnologists between the two preparations (Table 1).
- Sensitivity, NPV and accuracy positively correlated with the user's experience with the AI tool. For example, Cytotech A demonstrated superior sensitivity (88.0%/96.0%), NPV (88.9%/95.8%), and accuracy (92.0%/94.0%) compared to the other two less experienced cytotechnologists.
- Cytotech C, with the least experience, interpreted the most cases as negative, had the lowest sensitivity, NPV, and accuracy, but displayed the highest specificity and PPV.
- Reading times between the two preparations were consistent across all cytotechnologists (Figure 2).
- While Cytotech C took less time on negative slides (median 20-25 sec), the time spent on positive slides remained similar across all cytotechnologists (median 57-100 sec).

Conclusion

- Compared to the ground truth results (determined by microscopy), the AI-assisted tool demonstrated similar performance with the potential for greater efficiency in interpreting UTT cytology.
- The cytotechnologists' experience with the AI tool affected interobserver variation in performance and interpretation time, highlighting the importance of familiarity with the new digital technology.